



PATIENT

Fancy St Peters

SPECIES

Canine

BREED

Labrador Retriever

SEX

Female Intact

AGE

1 year

WEIGHT

60lbs

INTERPRETED BY

Maggie Machen
 Lamy, DVM, DACVIM
 (Cardiology)

IMAGING PERFORMED BY

Sara Hansen

HOSPITAL NAME

The Pet Clinic

REFERRING VET

NP

INVOICE

26488

DATE

9/21/22

PRESENTING CLINICAL SIGNS

History: Screening exam - service animal.

ELECTROCARDIOGRAPHIC FINDINGS *Note: Single lead ECGs are evaluated as a rhythm strip.

Morphology/MEA cannot be definitively commented on.

A single lead ECG is available; 50mm/s, 10mm/mV. The average heart rate is 105bpm (range 88-120bpm). The rhythm is sinus in origin, with a p for every QRS complex and vice versa. The P and QRS morphologies are positive. No ectopic beats, pauses or dysrhythmias observed.

ECG diagnosis: Normal sinus rhythm with respiratory variation.

ECHOCARDIOGRAM FINDINGS

2D, m-mode, color flow and doppler imaging is available. Normal mitral valve leaflets with no prolapse into the left atrial lumen. No mitral regurgitation with a normal left atrial dimension. Normal LV diameter with adequate myocardial function. The tricuspid valve appears normal with trivial tricuspid regurgitation. Normal right atrial and ventricular diameter and morphology indicating no overt evidence of pulmonary arterial hypertension. The pulmonic and aortic valves are normal in morphology and mobility. Normal pulmonic and aortic outflow velocities with laminar flow. No aortic or pulmonic insufficiency. No pericardial or pleural effusion noted. No obvious cardiac masses.

CARDIAC CHART

CANINE CARDIAC PARAMETERS	MR VMAX (m/s)	TR VMAX (m/s)	LA/AO (Boon method)	LA/AO (Heart Base; Swe)	FS (%)	EF (%)	EPSS (cm)
NORMAL PARAMETER	4.5-5.5	<2.7	1.3	<1.6	28-40	40-100	<0.6
PATIENT	NA	NA	1.4	1.1	37	67	0.3
CANINE CARDIAC PARAMETERS	HR (BPM)	AV VMAX (m/s)	PV MAX (m/s)	BODY WEIGHT (kg)	LA 2D short axis Base view (cm)	LVIDd Avg; 2D and m-mode short axis (cm)	LVIDs Avg; 2D and m-mode short axis (cm)
NORMAL PARAMETER	50-100	0.7-1.7	0.7-1.6	BELOW	BELOW	BELOW	BELOW
PATIENT	NM	1.4	1.0	27.2	2.4	4.2	2.7
*Normal chamber parameters expressed as a mean value (SD)				3	1.27 (5.3)	2.46 (2.46)	1.36 (5.5)
BODY WEIGHT DEPENDENT PARAMETERS				5	1.40 (4.5)	2.74 (5.2)	1.60 (4.7)
				10	1.50 (3.8)	3.27 (3.5)	2.06 (3.1)
Adapted from June Boon, Veterinary Echocardiography, 1998				15	1.83 (2.0)	3.71 (2.4)	2.43 (2.1)
Rishniw M and Hollis NE, J Vet Intern Med 2000; 14:429-435				20	2.02 (1.9)	4.14 (2.2)	2.80 (2.0)
Hansson et al, Vet Rad and Ultrasound 2002				25	2.18 (2.4)	4.48 (2.9)	3.10 (2.5)
Bonagura et al. Echocardiography: principles of interpretation, Vet Clin North Am 15:1177, 1995				30	2.33 (3.3)	4.83 (3.9)	3.39 (3.4)
				35	2.48 (4.3)	5.17 (5.0)	3.69 (4.5)
				40	2.62 (5.2)	5.48 (6.1)	3.96 (5.4)
				50	2.88 (7.1)	6.07 (8.3)	4.46 (7.4)



PATIENT

Fancy St Peters

SPECIES

Canine

BREED

Labrador Retriever

SEX

Female Intact

AGE

1 year

WEIGHT

60lbs

INTERPRETED BY

Maggie Machen Lamy, DVM, DACVIM
(Cardiology)

IMAGING PERFORMED BY

Sara Hansen

HOSPITAL NAME

The Pet Clinic

REFERRING VET

NP

INVOICE

26488

DATE

9/21/22

INTERPRETATION OF THE FINDINGS & FURTHER RECOMMENDATIONS

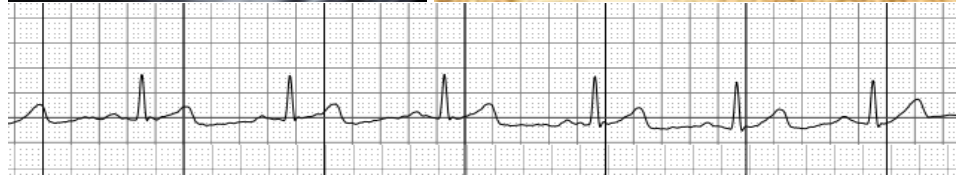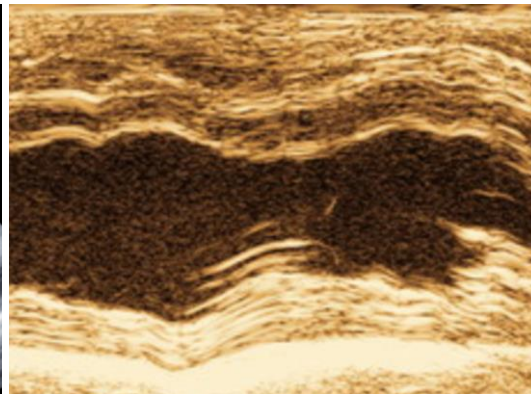
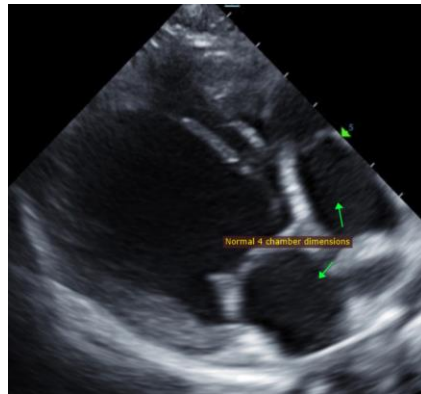
Overtly normal cardiac structural and function is identified. No significant valve leaks are appreciated, and the cardiac dimensions/function are normal. No obvious congenital issues are identified. The ECG is unremarkable with a normal sinus rhythm.

No obvious contraindication for breeding this animal. It should be noted that an OFA evaluation by an attending Cardiologist is the gold standard breed screening exam and should be considered in this animal if this is the intended use (congenital evaluation in addition to annual monitoring for development of cardiomyopathy).

Monitor for development of a heart murmur, cough, labored breathing, exercise intolerance or collapse episodes.

A recheck echocardiogram is recommended annually for breeding soundness, sooner if any clinical signs, murmur, etc. arise.

IMAGES



The information and recommendations provided are based on the images presented by the referring veterinarian. No evaluation can be communicated regarding pathology that was not visible in the image/video clips provided.

Thank you for this referral. This report was generated using transcription software, and minor dictation errors may be present. If the clinical or image interpretation does not parallel your findings or if I can be of any further assistance, please contact me.

Maggie Machen Lamy, DVM
Diplomate of the American College of Veterinary Internal Medicine (Cardiology)
info@sonopath.com